

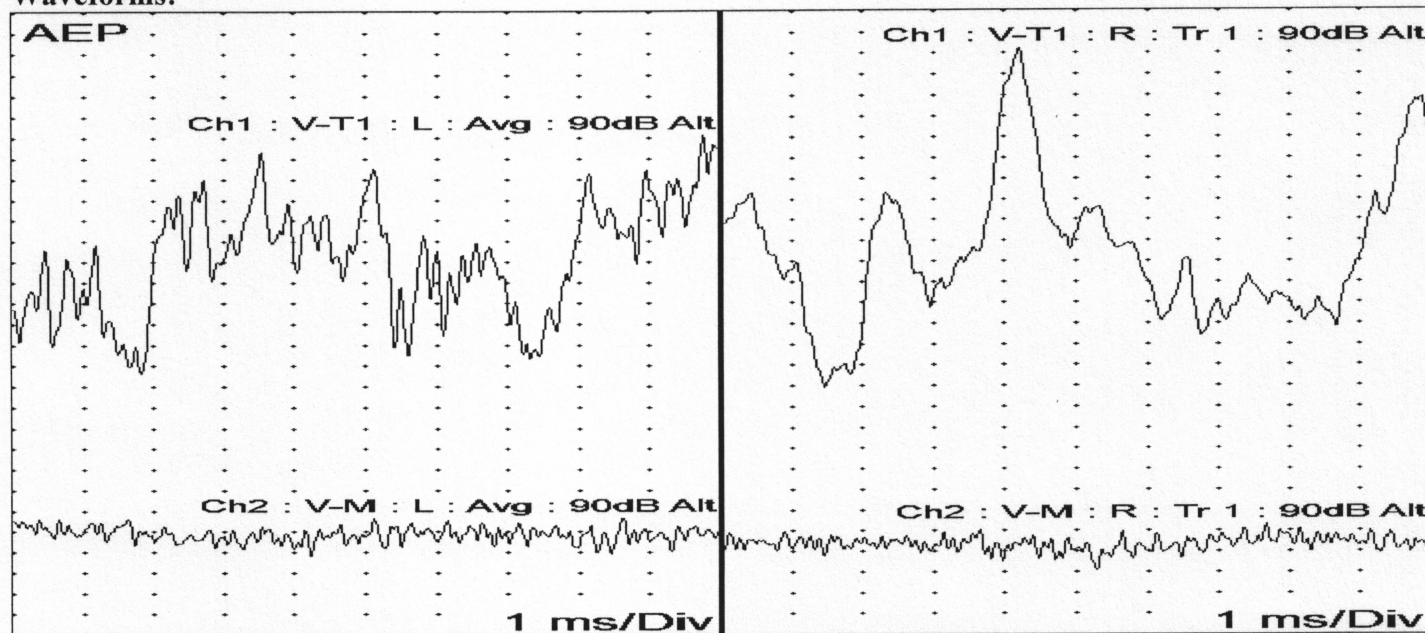
University of Illinois
Veterinary Teaching Hospital
1108 West Hazelwood Drive
Urbana, IL 61802
(217) 333-5300

Test Date: 6/22/2015

Patient: DN42804605 (Purple) Branson	DOB: 5/4/2015	Veterinarian: Devon Hague, DVM, DACVIM (Neurology)
Sex: Female	Species: Canine	
ID#: 100013	Weight: 3.6 kg	

Patient Complaints:
OFA BAER

Waveforms:



Impression: Normal BAER. Artifact present bilaterally, but waveform II and V present.